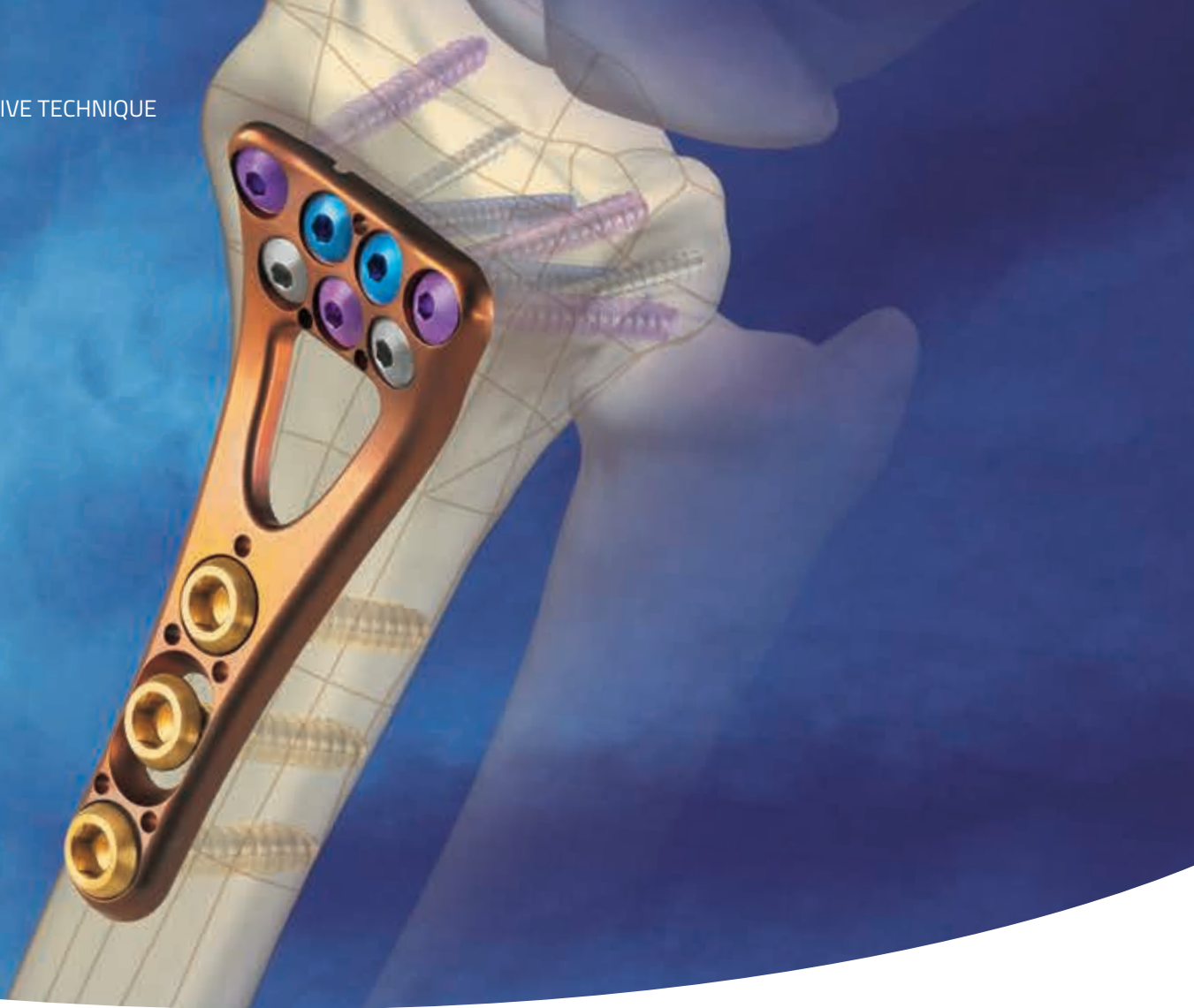



VOLAR PLATING WITH ANATOMICALLY DESIGNED PLATE AND FIXED-ANGLE SCREWS

INTRODUCTION	1
PRE-OPERATIVE TECHNIQUE	2
OPERATIVE TECHNIQUE	3
INSTRUMENTS	6
PART NUMBERS	8
INSTRUCTIONS FOR USE	12

Humanist 777 BT Light 9pt The surgical technique shown is for illustrative purposes only. The technique(s) actually employed in each case will always depend upon the medical judgment of the surgeon exercised before and during surgery as to the best mode of treatment for each patient. Please see Instructions for Use for the complete list of indications, warnings, precautions, and other important medical information.

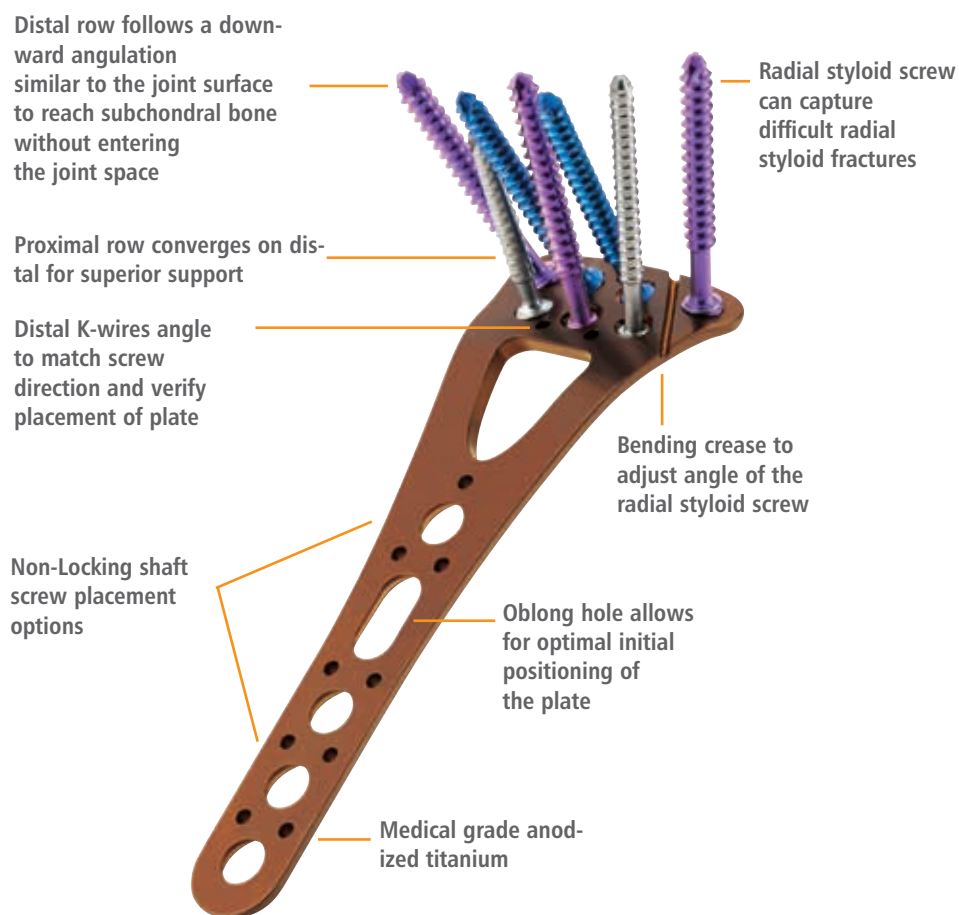
INTRODUCTION

The Orthofix Contours VPS combines locking screw technology with an anatomically designed plate to achieve fixed-angle screw placement with superior buttressing for volar and dorsal fracture displacement. The advantage of the fixed-angle design of the Contours VPS over the variable-angle fixed-angle designs is that, once the first screw is placed in an extra-articular, subchondral location, all the other screws should also be properly in subchondral bone, but not in the joint.

The Contours VPS anatomic design is based on cadaveric dissection, prepared bones, and digitized data gathered from the Hamann-Todd Osteological Collection. The volar surface geometry of the distal radius has substantial variability, most notably in the prominence of the lunate facet (called the lunate facet tuberosity, LFT), the volar radial

tuberosity (VRT), and the volar radial ridge (VRR). The Contours VPS is designed to accommodate the broad variances between patients caused by these structures for a more aligned bone-plate interface. The unique design of the Contours plate provides coverage for even the most difficult distal radius fractures, and avoids the need for multiple implants.


Contours VPS reduces the risk of improper plate and screw placement, and provides successful, reproducible outcomes.



SCREW TRAY CADDY

Screws color coded by characteristics

No misplaced screws - all screws have dedicated holes with matching depth




Measurement guide

Slightly elevated seat for easy grasp with screwdriver

Instrument Tray

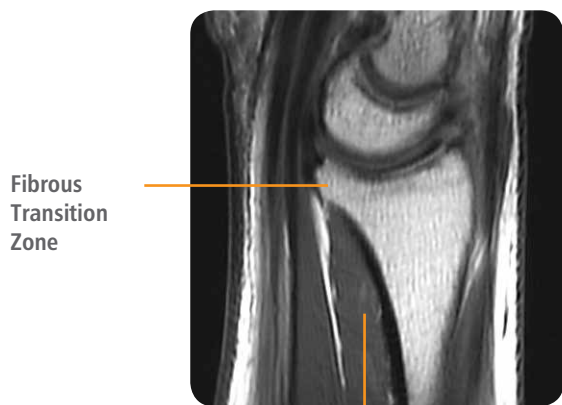
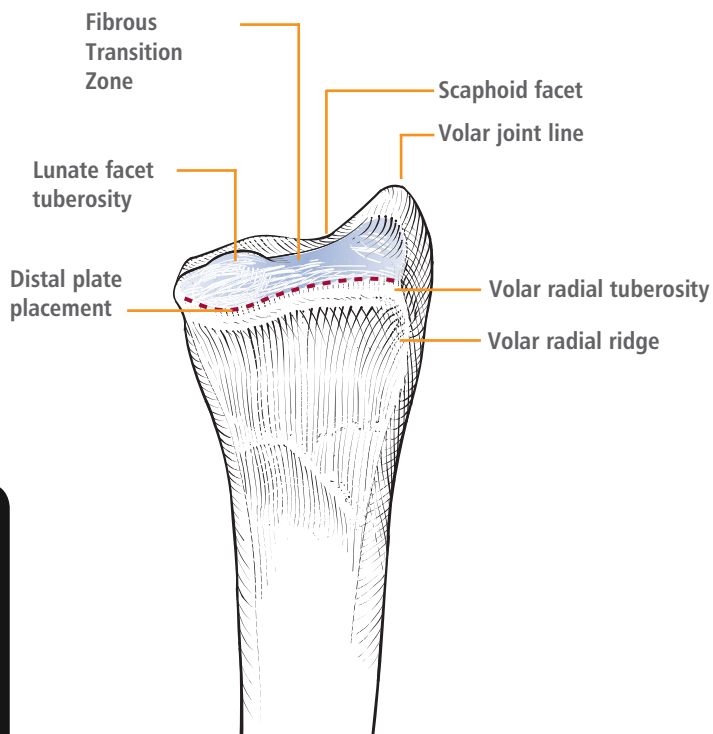
- Threaded drill guide can be used as an intra-operative handle for the plate.
- Threaded benders protect the integrity of the screw hole when adjusting at the bending crease.
- Ruled depth gauge for easy screw length determination.



SURGICAL ANATOMY

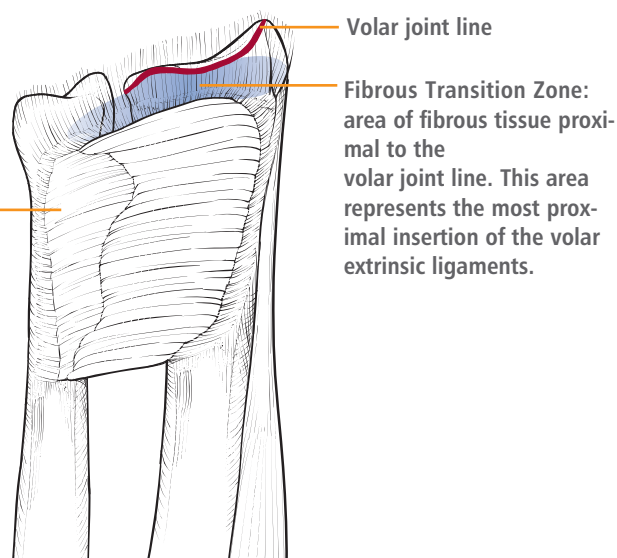
The volar surface geometry of the distal radius has substantial variability, most notably in the prominence of the lunate facet (called the lunate facet tuberosity, LFT), the volar radial tuberosity (VRT), and the volar radial ridge (VRR).

The area of fibrous tissue proximal to the volar joint line is referred to in this technique as the Fibrous Transition Zone (FTZ). This area represents the most proximal insertion of the volar extrinsic ligaments.



Fibrous Transition Zone

Pronator quadratus (PQ) muscle



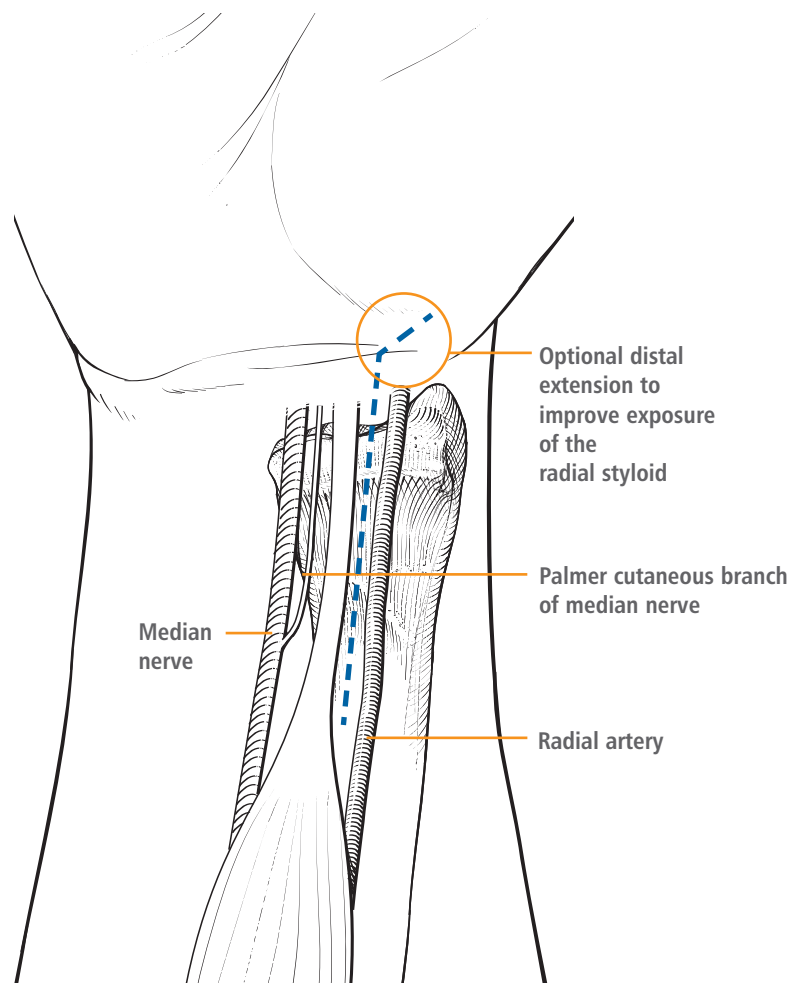
PRE-OPERATIVE PREPARATION

Contours VPS is designed to allow immediate motion without casts or splints. If the surgeon feels the specific case can sustain normal hand therapy loads, the best final range of motion and function will be achieved by starting hand therapy as soon as tolerable, usually within 3 days of surgery. Prior to surgery, discuss post-operative hand therapy with the patient and make arrangements for the first visit.

Perform a closed reduction, both to assess fracture fragment stability/movement and to make open reduction easier. Confirm with the C-arm.

VOLAR PLATING OF DISTAL RADIUS FRACTURES

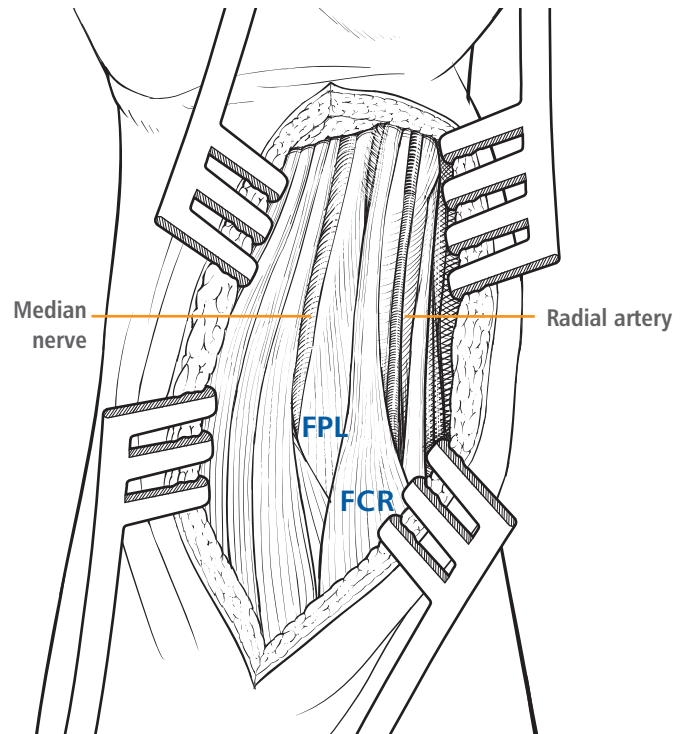
1. Place patient in supine position with hand extended on arm board. Prep hand, and apply finger trap traction if desired.
2. Make an incision using the flexor carpi radialis (FCR) approach, with distal extension as necessary. The FCR tendon is palpable radial to the palmaris longus, and is approximately centered over the radius. The skin incision should be centered over the FCR tendon and of approximately 10cm length. Generally, exposure may be facilitated by incising the septum between the FCR and the flexor pollias longus (FPL). Care should be taken to avoid the palmar cutaneous branch of the median nerve. (figure 1)



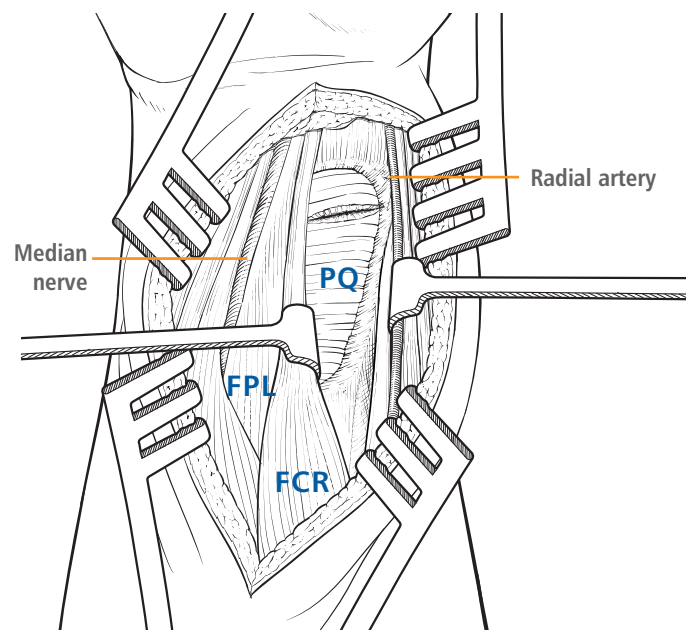
(figure 1)

3. Incise the fascia over the FCR and mobilize the tendon ulnarly to protect the radial nerve. Divide the floor of the FCR sheath, continuing the dissection distal to the skin incision for about 1/2cm distal to the wrist crease. Take care to avoid both the median nerve (in some cases it may be very close to the field) and the radial artery (in some cases a branch of it may cross just below the FCR tendon, distally). The floor of the FCR distally forms a thick septum between the FCR and the FPL. Failure to obtain enough distal exposure of the radius is usually due to inadequate division of this septum far enough distally. Radial column exposure may be facilitated by releasing the brachioradialis (BR) insertion from the radial styloid. (**figure 2**)

4. Mobilize the FPL ulnarly, releasing the muscle fibers from the radius. The median nerve is ulnar to the area of dissection, and the mobilized FPL will protect the nerve. The pronator quadratus (PQ) will be directly visualized with the distal portion usually obscured by the pre-muscular fat pad. The distal portion of the pronator quadratus is often torn. (**figure 3**)

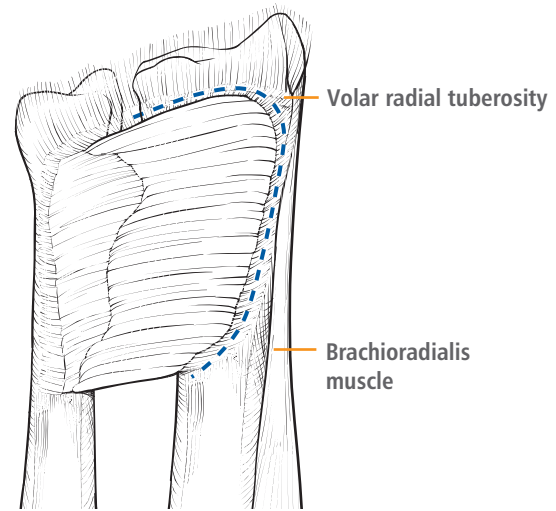


(figure 2)

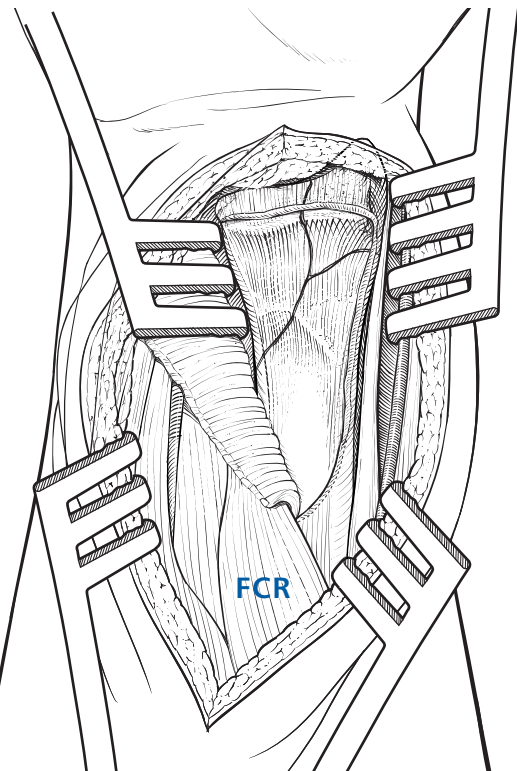


(figure 3)

5. Incise distally 1 to 2mm distal to the PQ distal border and release the PQ muscle from its radial attachment. Preservation of 1-2mm of fibrous tissue radially may facilitate repair of the PQ at the end of the case. (figure 4)
6. Reflect the PQ, clearing off enough of the radius to visualize from the volar radial tuberosity and volar radial ridge on the radial side to the distal radial ulnar joint (DRUJ) on the ulnar side, and the entire fracture site. Failure to visualize the entire width of the radius is generally due to lack of adequate release of the septum between the FCR and the FPL distally. Take care to protect the radial artery on the radial side and the median nerve on the median side. Distal exposure is dependent upon the fracture characteristics. In the presence of small distal fracture lines the FTZ may need to be elevated to achieve exposure of the fracture. **Care should be taken to avoid complete detachment of the volar extrinsic ligaments of the wrist from the palmar lip of the radius.** (figure 5)
7. Choose either the long or standard Contours VPS plate system based on the length of the fracture. For longer shaft fractures, use the long plate. Use the purple plate for the right wrist and the bronze plate for the left wrist.



(figure 4)



(figure 5)

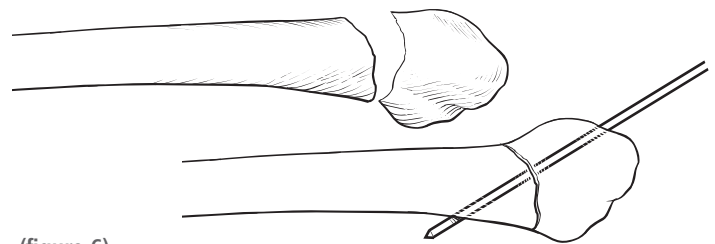


There is a choice of two techniques from this point: (A) Reduce the fracture first, then place the plate; (B) Place the plate and the distal screws first, reducing only the intra-articular fragments (if present), then secondarily use the plate to reduce the extra-articular component.

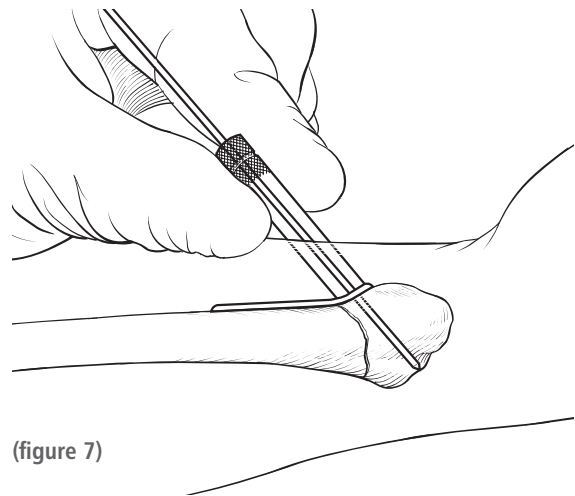
The choice of surgical technique depends on surgeon preference and fracture configuration.

SURGICAL OPTION A: REDUCE THE FRACTURE BEFORE PLACING THE PLATE

- A1. This technique requires the fracture to be easily reducible and stable, either by itself or by the placement of K-wires. If this is the technique chosen, free up the fracture fragments and reduce. If they are not stable, place K-wires as needed. (figure 6)
- A2. Examine the fracture configuration and decide on the most appropriate plate. The plate may not extend across the entire width of the radius. All that is required is the distal fragment be firmly held by the distal screws. Care must be taken to capture both any radial styloid fragment and any ulnar/dorsoulnar fragment. If there is a large central area of fracture lines, the plate must extend radially and ulnarly far enough to allow secure purchase of the distal fragments.
- A3. Place the plate as distally as possible, to engage the strong subchondral bone but still proximal enough to be out of the joint. Temporary fixation and alignment of the plate is accomplished by drilling a wire into a distal K-wire hole. Thread the drill guide into a distal K-wire hole and drill a K-wire through the guide and check its placement with fluoroscopy. (figure 7)



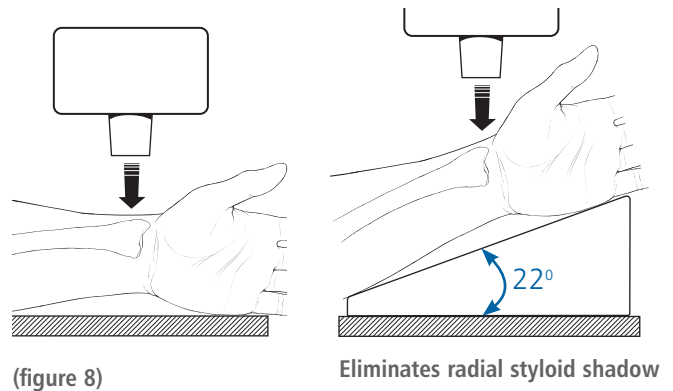
(figure 6)



(figure 7)

The tilted lateral view is taken with a pad under the hand to incline the radius 22° toward the beam. It eliminates the shadow of the radial styloid and provides a clear tangential view of the lunate facet. It is useful to assess residual depression of the palmar lunate facet and possible hardware penetration into the articular surface. (figure 8)

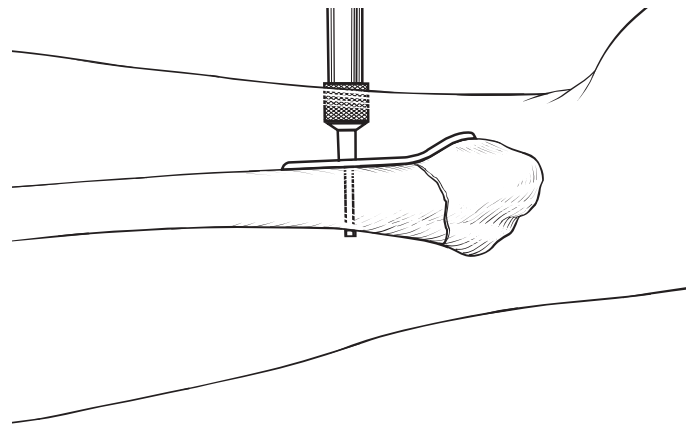
Use both the oblique lateral (called the “facet lateral” because it properly profiles the lunate facet) and the oblique PA (called the “facet PA”). The precise angle of the oblique depends on the angle of the facet you are interested in examining. Screw placement should be 4-5mm from the joint line as the strong subchondral bone provides the most secure screw purchase.



(figure 8)

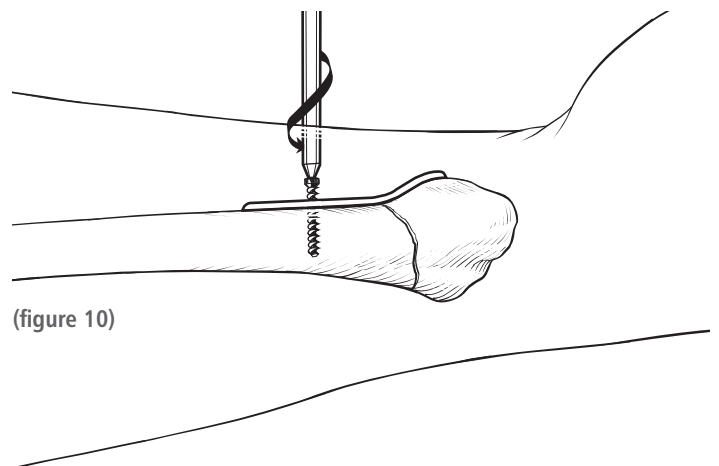
Eliminates radial styloid shadow

- A4. Next, pre-drill with the 2.5mm drill bit and place the 3.5mm proximal shaft screw in the oblong hole. Utilize the the depth gauge to determine proper length of the screws. Confirm proper plate position and apply proximal shaft screws as needed. (figure 9)



(figure 9)

Due to the design of the Contours VPS screws (rounded tips, micro cutting flutes and threads extending to the tip), full bicortical purchase can be obtained without extending more than 1mm beyond the far cortex. These screws should engage both cortices, as their security comes from bicortical purchase. Check the screw lengths with fluoroscopy. (figure 10)




(figure 10)

- A5. Once proper plate placement has been determined, choose the appropriate distal fixation screw style. The Orthofix Contours VPS provides four choices:
- a. 2.0mm microthread screws for the smallest, most fragile fragments
 - b. 2.4mm locking screws for small fragments
 - c. 2.7mm locking screws for larger fragments, and
 - d. 2.4mm non-locking lag screws.

The radial styloid is normally the largest fragment and a 2.7mm locking screw is used for greatest security. The 3.5mm cortical screw is for placement in the radial shaft.

Use the depth gauge to determine the proper screw length. (figure 11)

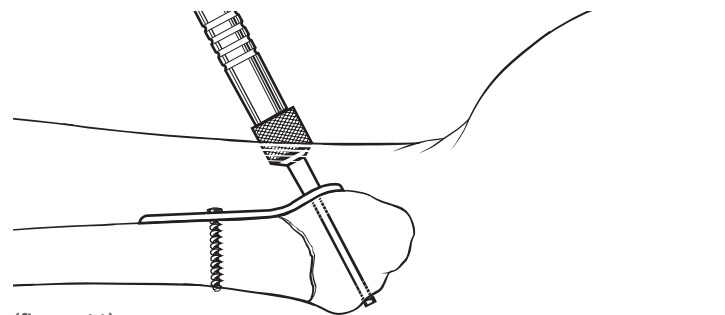


- A6. Drill the correct size hole:

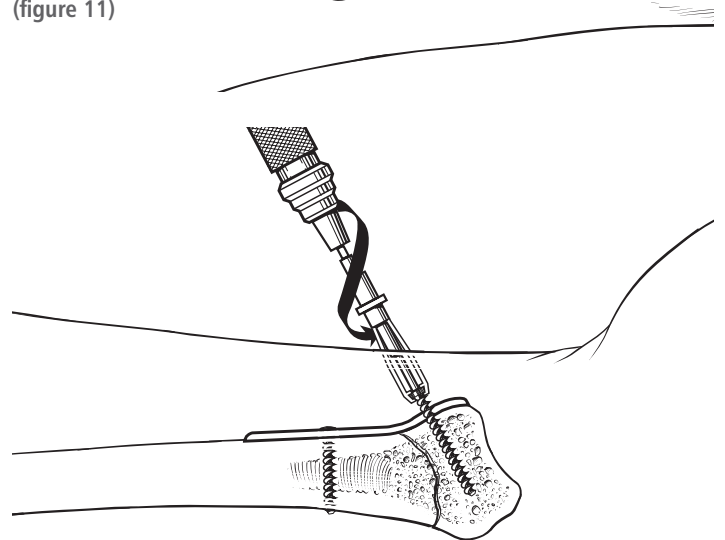
Screw size	Drill size
2.0mm microthread	1.6mm
2.4mm locking screw	2.0mm
2.4mm non-locking screw	2.0mm
2.7mm locking screw	2.0mm

Note: the distal screws should be about 2mm short of the dorsal cortex, for two reasons.

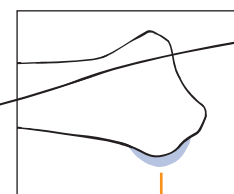
- a. The dorsal cortex provides little support. The security of the fixation comes from the screw placement into the subchondral bone.
- b. Screw prominence dorsally will impinge on the extensor tendons, which lie close to the bone and are held there by the extensor retinaculum and its vertical septae. Although the Orthofix Contours VPS pins and screws are rounded to avoid tendon injury, post-pointing must be avoided. Check the length of the screws with fluoroscopy, keeping in mind that Lister's tubercle may prevent you from visualizing the dorsal cortex and give a false impression of the location of the dorsal far cortex. (figure 12)



(figure 11)



(figure 12)



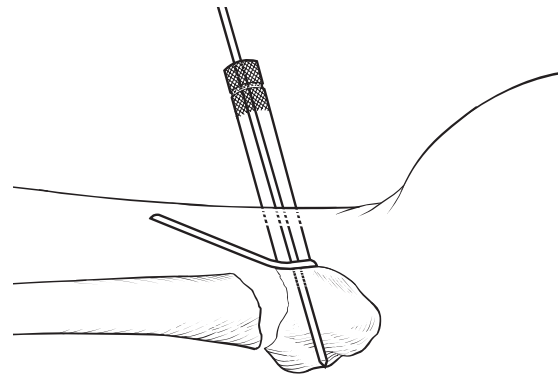
Shadow of Lister's tubercle

**SURGICAL OPTION B:
USE THE PLATE TO REDUCE DORSAL
ANGULATION**

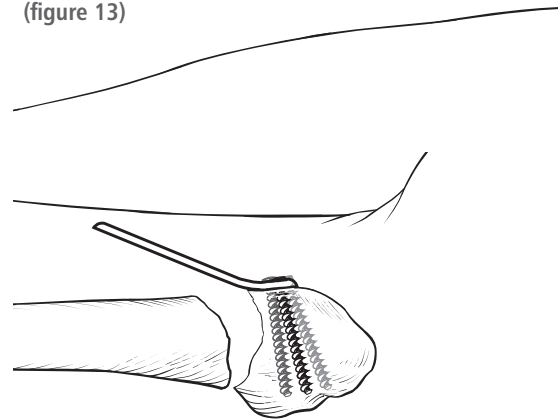
B1. This operative approach uses the plate to reduce the dorsal bending displacement (tilt). Apply the plate distally and verify there is no intraarticular penetration (*figure 13*)

Place the distal screws as noted in step A6 above. The screws should be secure and extend at least half the width of the radius, or the reduction maneuver will fragment the distal bone. As the screws are inserted, make sure the proximal shaft of the plate is aligned correctly over the radius. Once all the distal screws are placed: (*figure 14*)

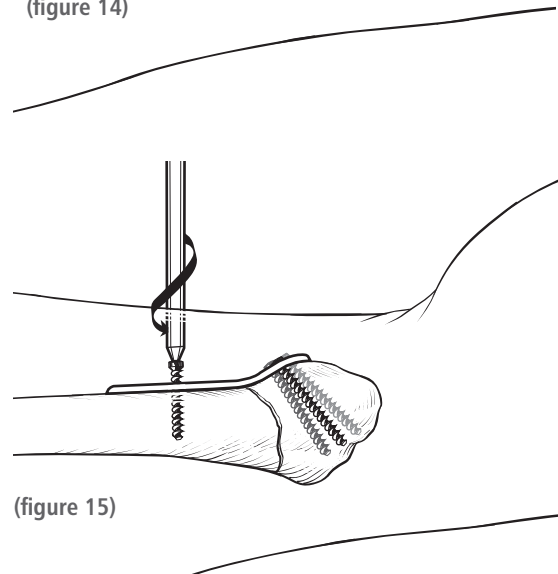
- a. The fracture line should be sufficiently mobile
- b. Reduce the distal fragment simultaneously as if doing a closed reduction and by lowering the plate down to the radial shaft. Never use the shaft as a simple lever, without simultaneously performing the above two points, or the distal fragment can be further fragmented. Place the shaft screw in the oblong hole and check it's length. (*figure 15*)
- c. Confirm reduction distal, to proximal, and place remaining screws as needed. Confirm screw length.



(figure 13)



(figure 14)



(figure 15)

8. Examine the plate to be sure it is not palpable externally, that the volar radial tuberosity does not hold the plate off the radius.

9. **Confirm that all screws are properly placed with their length appropriate to the location to avoid dorsal screw penetration through the far cortex and extensor tendon rupture.**

10. Check the DRUJ stability. If unstable, consider pinning the DRUJ or perform a soft tissue repair.

11. If possible, repair the PQ, utilizing the fibrous edge previously preserved to hold the suture securely. (figure 16)

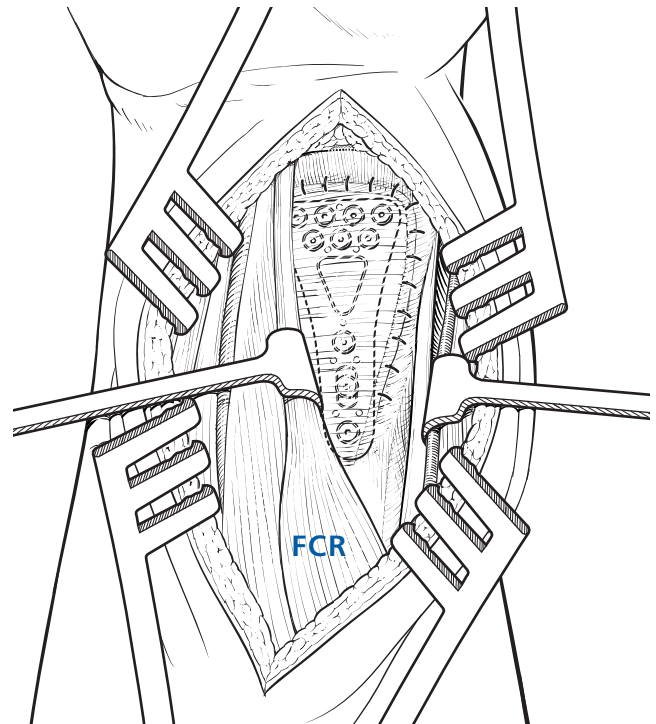
12. Close the skin.

Perform a final check for plate prominence and DRUJ instability.

POSTOPERATIVE MANAGEMENT

Contours VPS is designed to allow immediate motion without casts or splints if the surgeon feels the specific case can sustain these loads. To obtain the best final range of motion and function, Contours VPS patients should begin hand therapy as soon as tolerable, and usually within 3 days of surgery.

A block may be used to assist in post-operative pain control and contribute to earlier ROM therapy.



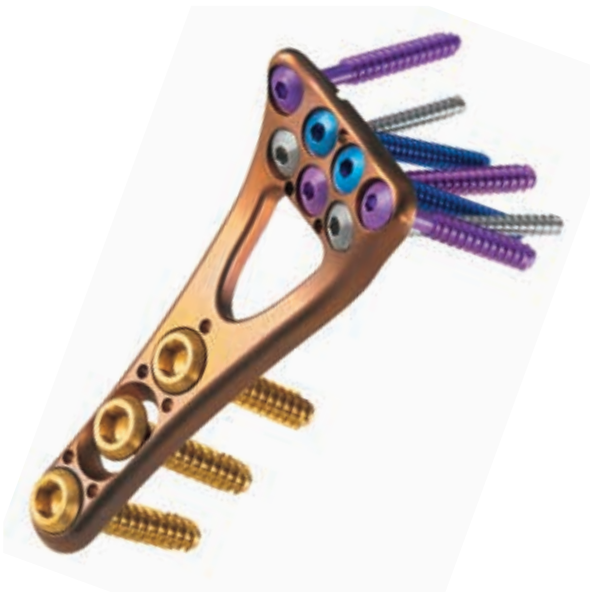(figure 16)

STERILIZATION

The Contours VPS Plate and Bone Screws are supplied NON-STERILE and require sterilization prior to use. The recommended, validated sterilization cycle is:

Method	Cycle	Temperature	Exposure Time
Steam	Pre-Vacuum (minimum 4 pulses)	132 -135 °C (270 -275 °F)	Minimum 10 minutes
Steam	Vacuum	132° C (270 °F)	10 minutes

The Contours VPS Plate and Bone Screws are intended for SINGLE USE ONLY.



ORDERING INFORMATION

Left Plates			
Catalog #	Left	Contour	Length
VPL0309CE	Left	Standard	Standard
VPL0310CE	Left	Standard	Long

Right Plates			
Catalog #	Left	Contour	Length
VPR0321CE	Right	Standard	Standard
VPR0322CE	Right	Standard	Long

3.5mm Non Locking Cortical Screws		
Catalog #	Thread Diameter	Screw Length
PSC3512TCE	3.5mm	12mm
PSC3514TCE	3.5mm	14mm
PSC3516TCE	3.5mm	16mm
PSC3518TCE	3.5mm	18mm
PSL3520TCE	3.5mm	20mm

2.4mm Non-Locking Screws		
Catalog #	Thread Diameter	Screw Length
PSC2414TCE	2.4mm	14mm
PSC2416TCE	2.4mm	16mm
PSC2418TCE	2.4mm	18mm
PSC2420TCE	2.4mm	20mm
PSC2422TCE	2.4mm	22mm

2.4mm Locking Screws		
Catalog #	Thread Diameter	Screw Length
PSC24P12TCE	2.4mm	12mm
PSC24P14TCE	2.4mm	14mm
PSC24P16TCE	2.4mm	16mm
PSC24P18TCE	2.4mm	18mm
PSC24P20TCE	2.4mm	20mm
PSC24P22TCE	2.4mm	22mm
PSC24P24TCE	2.4mm	24mm

2.0mm Locking, MicroThreaded Screws		
Catalog #	Thread Diameter	Screw Length
PSC2014TCE	2.0mm	14mm
PSC2016TCE	2.0mm	16mm
PSC2018TCE	2.0mm	18mm
PSC2020TCE	2.0mm	20mm
PSC2022TCE	2.0mm	22mm
PSC2024TCE	2.0mm	24mm

2.7mm Locking Screws		
Catalog #	Thread Diameter	Screw Length
PSC2714TCE	2.7mm	14mm
PSC2716TCE	2.7mm	16mm
PSC2718TCE	2.7mm	18mm
PSC2720TCE	2.7mm	20mm
PSC2722TCE	2.7mm	22mm
PSC2724TCE	2.7mm	24mm
PSC2726TCE	2.7mm	26mm
PSC2728TCE	2.7mm	28mm

Instruments	
Catalog #	Description
VP601CE	Steri-Tray, Empty
DH0411CE	3.0mm Hex Driver
DH0412CE	Bender, Straight Plate
DH0413CE	Bender, Threaded Plate
DH0416CE	Drill Guide, 2.5mm
DH0421CE	K-Wire, 1.1 x 150mm
DH0422CE	Hex L Key
DH0426CE	Depth Gauge, Distal
DH0427CE	Depth Gauge, Proximal
DH0437CE	1.5 Hex Driver (Tip Only)
DH0439CE	1.5 Hex Driver
DH0432CE	Drill Guide, 1.6mm
DH0433CE	Drill Guide, 2.0mm
DH0434CE	Drill Bit, 1.6mm
DH0435CE	Drill Bit, 2.0mm
DH0436CE	Drill Bit, 2.5mm



Manufactured by:
ORTHOFIX Srl
Via Delle Nazioni 9, 37012 Bussolengo (Verona), Italy
Telephone +39 045 6719000, Fax +39 045 6719380



Distributed by:



Instructions for Use: See actual package insert for Instructions for Use.

Caution: Federal law (USA) restricts this device to sale by or on the order of a physician. Proper surgical procedure is the responsibility of the medical professional. Operative techniques are furnished as an informative guideline. Each surgeon must evaluate the appropriateness of a technique based on his or her personal medical credentials and experience. Please refer to the "Instructions for Use" supplied with the product for specific information on indications for use, contraindications, warnings, precautions, adverse reactions and sterilization.

www.orthofix.com

CV-0702-OPT-E0 C 12/16

